



Published in final edited form as:

*J Am Acad Dermatol.* 2012 August ; 67(2): 289–304. doi:10.1016/j.jaad.2011.11.938.

## An overview of clinical and experimental treatment modalities for port wine stains

Jennifer K. Chen, MD<sup>a</sup>, Pedram Ghasri, MD<sup>a</sup>, Guillermo Aguilar, PhD<sup>b</sup>, Anne Margreet van Drooge, MD<sup>c</sup>, Albert Wolkerstorfer, MD, PhD<sup>c</sup>, Kristen M. Kelly, MD<sup>a</sup>, and Michal Heger, PhD<sup>d,e</sup>

<sup>a</sup>Beckman Laser Institute and Medical Clinic, University of California, Irvine

<sup>b</sup>Department of Mechanical Engineering, University of California, Riverside

<sup>c</sup>The Netherlands Institute for Pigment Disorders, Department of Dermatology, Academic Medical Center, University of Amsterdam

<sup>d</sup>Department of Experimental Surgery, Academic Medical Center, University of Amsterdam

<sup>e</sup>Biochemistry of Membranes, Institute of Biomembranes, University of Utrecht

### Abstract

Port wine stains (PWS) are the most common vascular malformation of the skin, occurring in 0.3% to 0.5% of the population. Noninvasive laser irradiation with flashlamp-pumped pulsed dye lasers (selective photothermolysis) currently comprises the gold standard treatment of PWS; however, the majority of PWS fail to clear completely after selective photothermolysis. In this review, the clinically used PWS treatment modalities (pulsed dye lasers, alexandrite lasers, neodymium:yttrium-aluminum-garnet lasers, and intense pulsed light) and techniques (combination approaches, multiple passes, and epidermal cooling) are discussed. Retrospective

---

© 2011 by the American Academy of Dermatology, Inc.

Reprint requests: Michal Heger, PhD, Department of Experimental Surgery, Academic Medical Center, University of Amsterdam, Meibergdreef 9, 1105 AZ Amsterdam, The Netherlands. M.Heger@amc.uva.nl.

Disclosure: Dr Aguilar was a consultant for Aesthera and Lumenis. Dr Heger holds intellectual property rights regarding site-specific pharmaco-laser therapy. Drs Chen, Ghasri, van Drooge, Wolkerstorfer, and Kelly have no conflicts of interest to declare.

Some of the topics addressed in this review were presented at conferences. Michal Heger: Annual meetings of the American Society for Laser Surgery and Medicine (April 2006, Boston, MA; April 2009, Washington DC; April 2011, Grapevine, TX). Guillermo Aguilar: "Significant improvement in cryogen-assisted dermatologic laser therapy through the use of local vacuum," talk presented at ASLMS, Dallas TX, April 2004; "Thermal interaction of cryogen spray with human skin under vacuum pressures," talk presented at the 10th Latin American Congress in Heat and Mass Transfer (LATCyM), Caracas, Venezuela, April 2005; "Interaction of cryogen spray with human skin under vacuum pressures," talk presented at the 2005 Fluid Structure Interaction Conference of the Wessex Institute of Technology, La Coruña, Spain, September 2005; "Numerical model of vacuum assisted laser therapy with the aid of cryogen spray cooling for treatment of port wine stains," talk presented at the 11th Latin American Conference of Heat and Mass Transfer (LATCyM), September 6–8, 2006, Mexico City, Mexico; "New trends on the use of thermo-mechanical procedures to assist laser medical applications," plenary talk speaker at the 30th International Conference on Surfaces, Materials and Vacuum 2010, Playa Paraíso-Riviera Maya, Mexico, Sept 27-Oct 1st, 2010; Kristen Kelly: "Combined photodynamic and pulsed dye laser treatment of port wine stains," presented at the American Society for Laser Medicine and Surgery Annual Meeting, 2006, Boston, MA; "Vascular effects of bevacizumab and pulsed dye laser protocols," presented at the American Society for Laser Medicine and Surgery Annual Meeting, 2008, Orlando, Florida; "Combined therapy for enhanced microvascular destruction in port wine stains: Pulsed dye laser photothermolysis and imiquimod," presented at Annual Meeting for American Society of Laser Medicine and Surgery, April 1–5 2009, Washington, DC; "Angiogenesis mediator alterations in angiomas after pulsed dye laser treatment," Annual Meeting of the American Society of Laser Medicine and Surgery, April 1, 2011, Dallas, TX; "Lasers and lights for vascular lesions: New and exciting opportunities," Controversies and Conversations in Laser and Cosmetic Surgery, August 2011, Asheville, NC.

analysis of clinical studies published between 1990 and 2011 was performed to determine therapeutic efficacies for each clinically used modality/technique. In addition, factors that have resulted in the high degree of therapeutic recalcitrance are identified, and emerging experimental treatment strategies are addressed, including the use of photodynamic therapy, immunomodulators, angiogenesis inhibitors, hypobaric pressure, and site-specific pharmaco-laser therapy.

### Keywords

angiogenesis inhibitors; epidermal cooling; hypobaric pressure; immunomodulators; photodynamic therapy; pulsed dye laser; site-specific pharmaco-laser therapy; superficial vascular and capillary malformations

---

Port wine stains (PWS) are congenital vascular lesions characterized by ectatic capillaries and postcapillary venules (typically 30–300  $\mu\text{m}$  in diameter) in the papillary and mid-reticular layers of the dermis. These birthmarks occur in 0.3% to 0.5% of infants and initially appear as flat, pink to red patches that may gradually progress with age into hypertrophic, red to purple lesions.<sup>1–3</sup> By age 46 years, two thirds of affected individuals develop papular or nodular components and soft tissue overgrowth, causing dysmorphism, asymmetry, and occasional spontaneous bleeding.<sup>4,5</sup> In addition, the aberrant cosmetic appearance of PWS may significantly impede the patient's psychosocial development and well-being, and because 70% to 80% of these birthmarks occur in the head and neck regions, many patients seek treatment.<sup>6–8</sup>

Pulsed dye laser (PDL) remains the gold standard of treatment; however, despite technological advances, a considerable number of patients with PWS still do not achieve complete lesion removal with PDL treatment. This overview provides an update on the current status of light-based PWS treatment strategies and addresses several experimental modalities that may prove promising in the treatment of refractory PWS.

## LASER TREATMENT OF PWS

Current laser systems treat PWS via the principle of selective photothermolysis. PDL therapy has remained the clinical gold standard and has inspired the development of other laser and intense pulsed light (IPL) systems and ancillary technologies.

### Causes of PWS recalcitrance to laser therapy

The efficacy of the PDL and other current laser systems is accorded by the principle of selective photothermolysis, illustrated in Fig 1 along with the underlying endovascular laser-tissue interactions and subsequent biological responses that lead to PWS clearance. Clinically, complete photocoagulation of the target vessels is associated with good lesional clearance,<sup>9</sup> representing approximately 40% of cases.<sup>10</sup> Incomplete photocoagulation of PWS vasculature is associated with suboptimal to no clearance, which prevails in 20% to 46% and 14% to 40% of patients, respectively, for several reasons.<sup>9–12</sup>

First, the efficacy of selective photothermolysis depends on the extent of epidermal pigmentation,<sup>13–16</sup> optical shielding by blood and superimposed vessels,<sup>9,11,12,17–19</sup> and PWS vascular anatomy and morphology.<sup>9,11,18–21</sup> Generally, factors resulting in decreased treatment efficacy include those that reduce light penetration, such as superimposed vasculature, high melanin content, and an increased PWS vascular density, diameter, or depth.<sup>8,20</sup> PWS vessels have been found in the reticular plexus up to a depth of 3.7 mm, albeit most of the ectatic vasculature is located within approximately 0.6 mm of the basal membrane.<sup>2,11,22,23</sup> Second, angiogenic remodeling is poorly understood. Lesional clearance requires the replacement of photo-coagulated hyperdilated PWS vasculature by normal-sized, lower-volume capillaries (Fig 1), resulting in a reduction in dermal blood content and hence PWS redness. In therapy-recalcitrant PWS, angiogenesis/ neovasculogenesis<sup>24</sup> likely occurs too extensively during the short-term vascular remodeling phase and hampers the reduction in dermal blood content.<sup>25</sup>

### Pulsed dye lasers

In the 1980s, the clinical introduction of the yellow light-emitting PDL revolutionized the treatment of PWS. The first PDL system used a wave-length of 577 nm and a pulse duration ranging from 300 to 400 microseconds.<sup>26</sup> The 577-nm wavelength was selected on the basis of the oxyhemoglobin absorption peak and a lower melanin-to-hemoglobin absorption coefficient ratio compared to the wavelengths of the argon laser (488 nm, 514 nm). To confer target selectivity, the pulse duration was longer than the thermal relaxation time of the dermal microvessels but shorter than the thermal relaxation time of PWS vasculature.<sup>17</sup> However, the 577-nm PDL did not penetrate deeply enough into tissue to enable optimal lesion clearance.<sup>26–32</sup>

In the 1990s, the 585-nm PDL became an attractive clinical alternative with its lower melanin and (oxy) hemoglobin absorption coefficient.<sup>18,33–51</sup> Using an albino pig skin model, it was shown that the penetration depth could be increased from 0.5 mm (577 nm) to 1.2 mm (585 nm) below the basal membrane while retaining vascular selectivity.<sup>52</sup> Histologic studies<sup>9,11</sup> of human skin have revealed that photocoagulation occurs to a depth of approximately 0.65 mm after 585-nm PDL treatment at a 0.45-millisecond pulse duration, 5-mm spot size, and radiant exposure of 6 to 8 J/cm<sup>2</sup>. At these settings, complete photocoagulation of the vessel lumen occurs in superficial vessels up to approximately 150  $\mu$ m in diameter.<sup>11</sup> Larger and deeper vessels, however, remain patent, owing to both shielding by superficial vessels and inadequate penetration depth.<sup>17,53</sup> This, in combination with the greater absorption of light by oxyhemoglobin at 577 nm, may account for the lack of significant improvement in lesional clearance rates for the 585-nm PDLs compared to the 577-nm PDLs (see “Status quo” section).

Subsequently, longer PDL wavelengths have been used to further enhance the depth of photocoagulation and thus lesional clearance. A study by Geronemus et al<sup>54</sup> found that the 595-nm PDL is capable of yielding clearance rates of more than 75% in 62% of patients after an average of 3.2 treatments, without adverse events. However, subsequent studies with the 595-nm PDL failed to reproduce these results.<sup>55–58</sup>

In addition to wavelength, other laser parameters such as pulse duration and spot diameter have been varied to further improve PWS clearance rates. The implementation of multiple pulse durations may be especially effective for PWS resistant to treatment at one particular pulse duration or PWS that are composed of vessels of different diameters. The ideal pulse duration for blood vessels of 20 to 150  $\mu\text{m}$  has been suggested to range from 1 to 10 milliseconds, which is considerably longer than the 0.45-millisecond pulse width of initial PDL systems.<sup>59</sup> Indeed, an increase in PDL pulse width from 0.45 milliseconds to 1.5, 3, and 10 milliseconds has been noted to cause improvement in treatment outcome.<sup>55,57,60–62</sup> However, the therapeutic benefit may be limited to vessels greater than 30  $\mu\text{m}$  in diameter.<sup>57</sup> It is also important to note that higher fluences may be required when using longer pulse durations.<sup>63</sup>

With respect to spot size, increasing beam diameters allow greater tissue penetration to more effectively target larger and deeper vascular structures, and offer more uniform energy transmission and shorter treatment times.<sup>64</sup> Per unit of radiant energy expended, large spot sizes produce increased volumetric heat production with improved efficiency, but greatly limit the acceptable maximum fluence. To avoid losing specificity, the spot size should not be larger than the target lesion, and commonly ranges from 7 to 10 mm.

### **Alexandrite laser (755 nm)**

The 755-nm alexandrite laser has been shown to effectively treat hypertrophic or nodular lesions, which may be associated with deeper blood vessels.<sup>65–68</sup> This laser system has proven particularly useful in the treatment of hypertrophic and PDL-resistant PWS,<sup>65,69</sup> especially when used in conjunction with the PDL. A study on the PDL/ alexandrite laser dual approach ( $\lambda =$  undisclosed wavelength/755 nm) demonstrated significant lightening in all of 3 patients with hypertrophic PWS and moderate lightening in 12 of 17 patients with PDL-resistant PWS.<sup>69</sup>

The therapeutic efficacy of the alexandrite laser has been attributed to several factors. First, the 755-nm wavelength falls inside the therapeutic window: with less absorption by melanin as compared to yellow wavelengths, light is able to penetrate more deeply into tissue. Second, the 755-nm wavelength is more strongly absorbed by deoxyhemoglobin than by oxyhemoglobin, and in theory should preferentially damage venules (ie, PWS vasculature) over arterioles.

It is important to bear in mind that longer wave-length lasers are associated with elevated risk of adverse events such as pigmentary changes and scarring, owing to the deeper tissue penetration and decreased absorption by hemoglobin, which necessitates the use of higher fluences. In the case of the alexandrite laser, it has been recommended to treat only until achieving a subtle gray-blue darkening of the skin that, within several minutes, evolves into deeper purpura.<sup>70</sup> The fluence threshold for such a response is best determined in the darkest PWS area, where this threshold is lowest.

### **Neodymium:yttrium-aluminum-garnet lasers (1064 nm, 532 nm)**

As with other longer wavelength lasers such as the alexandrite laser, the 1064-nm neodymium:yttrium-aluminum-garnet (Nd:YAG) laser can further reduce optical scattering

and melanin absorption. Promising results have been obtained especially in purple, hypertrophic, and nodular PWS lesions. Yang et al<sup>66</sup> reported that this laser system was as effective as the PDL for treating PWS when used at the minimal purpura dose, and our group has achieved relatively high clearance rates in specific patient cohorts.

As with the alexandrite laser, because of the lower hemoglobin absorption and relatively high water absorption at 1064 nm, higher fluences are required for sufficient photocoagulation, concomitantly causing nonselective bulk heating. Thus, the 1064-nm Nd:YAG laser can result in significant scarring when using fluences greater than 1.2 times the minimal purpura dose.<sup>66</sup> This makes safe treatment of anatomically heterogeneous vascular lesions such as PWS difficult. Moreover, the therapeutic response and tolerance varies greatly among PWS lesions, which further limits the use of the 1064-nm laser in general practice. Such therapy is best performed by those with experience with these devices.

Another treatment option is the PDL/Nd:YAG dual laser approach ( $\lambda = 595 \text{ nm}/1064 \text{ nm}$ ): the initial 595-nm pulse causes a chromic shift from oxyhemoglobin to methemoglobin, which has a significant absorption peak near 1064 nm. Consequently, the Nd:YAG laser pulse is rendered more effective, whereby the synergistic thermal effect decreases the amount of fluence necessary for adequate photocoagulation, potentially reducing bystander tissue damage. This dual laser approach has been successfully used for recalcitrant and hypertrophic PWS.<sup>67</sup>

Alternatively, the frequency-doubled 532-nm Nd:YAG laser has been used to induce homogenous heating of large-diameter blood vessels. It has also been shown to have some efficacy in pink, flat, PDL-resistant PWS.<sup>71</sup> Nevertheless, irradiating skin with 532-nm light is associated with greater risk of adverse effects as a result of predominant absorption by melanin, despite epidermal cooling.<sup>72,73</sup> The clinical applicability of the 532-nm laser may hence be limited.

### **Intense pulsed light**

IPL has also been reported to be an effective alternative to PDL for treatment of PWS.<sup>74</sup> The IPL flashlamps generate noncoherent light with wave-lengths between 515 to 1200 nm, while integrated filters remove unwanted wavelengths for more specific targeting. Although IPL has been shown to be effective in the clearance of pink and red PWS,<sup>74-80</sup> a head-to-head trial comparing the efficacy of IPL against PDL determined that the median clinical improvement was significantly better for PDL (65%) than IPL (30%).<sup>81</sup> Nevertheless, IPL can be considered for treating PDL-resistant PWS.

### **Multiple-pass approaches**

The extent of vascular damage may be increased by the use of multiple-pass techniques, although this has been controversial.<sup>82-85</sup> In the treatment of hypertrophic PWS, the administration of a second pass has been reported to be safe and effective in 4 patients.<sup>82</sup> Another study, however, used the same technique and settings in 33 patients with PWS and could not confirm the benefit of a second pass over conventional single-pass treatment.<sup>83</sup> More recently, a retrospective review of 26 patients, all of whom had received a minimum

of 3 treatment sessions with double-pass PDL using an interpulse interval of 20 to 30 minutes,<sup>85</sup> reported clinically significant PWS lightening in only 5 of 26 patients. Sixteen of the 26 patients developed mild adverse effects in the form of blisters, dry scabs, and transient hyperpigmentation. Tanghetti et al,<sup>84</sup> based on histologic assessment of vascular damage of non-PWS skin, suggested that multiple-pass PDL treatment may be beneficial but stressed the relevance of the interval between pulses. At minimal purpuric doses, they demonstrated an increase in the depth of vascular damage from 0.7 to 1.3 mm with an increasing interpulse interval of up to 60 seconds. Further increase of the interpulse interval to 5 or 30 minutes resulted in a similar depth of vascular injury as single-dose treatments. In contrast, treatment above purpura threshold resulted in increased depth of damage with increasing interpulse intervals up to at least 30 minutes. All interpulse intervals were tolerated well with no adverse effects other than transient purpura. Altogether, multiple passes may be beneficial but further evidence is needed.

### Epidermal cooling

Epidermal melanocytes constitute a major limitation to laser therapy, as they have the capacity to absorb a significant portion of the laser energy and mediate laser-induced scarring and pigmentary damage. Consequently, irradiances must be chosen such that adequate venular heating is achieved without generating excessive temperatures at the basal membrane. This has proven rather challenging, as unequivocal objective parameters to determine the optimal irradiance are currently lacking. With the advent of epidermal cooling technology, however, it has become possible to minimize nonselective epidermal thermal injury and concurrently use higher fluences to treat PWS more effectively.<sup>10,14,54–58,86–99</sup> Cooling also has the added advantage of significantly reducing the patient's level of pain and discomfort. As a result, the majority of modern clinical laser systems are equipped with integrated cooling technology.

Primary cooling methods include contact cooling, cold air cooling, and cryogen spray cooling.<sup>100</sup> Cryogen spray cooling is currently the method of choice of the authors, as we believe it can selectively cool the epidermis and perivascular tissue while minimally affecting the temperature of the underlying blood vessels.<sup>86</sup>

### Status quo

To compare PWS clearance rates among different laser systems, ancillary technologies, and treatment modalities, retrospective analysis was performed of clinical studies published between 1990 and currently, in which patient outcomes were classified according to putative scoring systems. The data are summarized in Fig 2, and the complete data set is provided in Table I (available online at <http://www.jaad.org>).<sup>10,14,18,26–51,54–58,62,65–69,71–82,86–99,101–112</sup>

Review of the literature shows that a large population of patients with PWS respond poorly to laser treatment, with a range of 12% to 85% of patients achieving less than 50% clearance, regardless of the treatment modality (Fig 2). Despite all advances, no substantial progress in clinical outcomes has been made over the last 20 years. Interestingly, the 577-nm and 585-nm PDLs appear to yield better clinical results than the more modern laser

systems, although this may be explained by differences between populations of patients with PWS and the gradual transition to more objective scoring methodologies. Nevertheless, there is a clear necessity for the continued development and implementation of alternative treatment strategies for refractory PWS.

## EXPERIMENTAL TREATMENT MODALITIES

There are a number of promising experimental therapies for PWS currently being investigated. In this section, several of these modalities are addressed, including photodynamic therapy (PDT), angiogenesis inhibitors, hemodynamic alterations in PWS vasculature, and site-specific pharmaco-laser therapy (SSPLT).

### Photodynamic therapy

Based on the results of a chicken comb model study, in 1990 Orenstein et al<sup>113</sup> proposed the use of PDT to selectively treat hypervascular dermal lesions without inducing epidermal damage. In 1994, a 3-year clinical study corroborated that PDT can be successfully used for the treatment of PWS.<sup>114</sup> Since then, many studies have evaluated the use of PDT for the treatment of PWS, both as a solitary and as a synergistic treatment modality. Retrospective analysis was performed of clinical studies using PDT for the treatment of PWS published between 1990 and currently, in which patient outcomes were classified according to putative scoring systems. The summary of results is presented in Fig 3 and the complete data set is provided in Table II (available online at <http://www.jaad.org>).<sup>115–121</sup>

PDT involves the activation of a photosensitizer by visible light. The absorption of light triggers a photochemical-biological reaction that, in the presence of oxygen, leads to reactive oxygen species generation that in turn causes direct endothelial cell damage, thrombosis, and shutdown of vasculature.<sup>117</sup> Oxidative cell damage is limited to those photoilluminated areas containing sufficient photosensitizer concentrations,<sup>122</sup> as the short diffusion distance of reactive oxygen species ( $\approx 0.1 \mu\text{m}$ ) limits collateral damage to minimal to none. These aspects impart site specificity to PDT that is similar to selective photothermolysis. The efficacy of PDT depends on factors such as wavelength and light intensity, exposure time, and choice of photosensitizer.

It has been suggested that the therapeutic efficacy of PDT is equivalent or even superior to PDL treatment. One retrospective study of 581 patients compared the 585-nm PDL at 0.45-millisecond pulse duration with PDT using intravenously administered hematoporphyrin monomethyl ether and the 578-nm copper vapor laser.<sup>120</sup> There was no statistically significant difference in lesional blanching in children, whereas lesional blanching in adults was achieved in 88.4% of patients treated with PDL and in 94.2% of patients treated with PDT. Near-complete clearance was higher in the PDT group (37.5%) than in the PDL group (3.1%). Moreover, complications were higher in the PDL than in the PDT group (24.7% vs 10.2%, respectively), with adverse effects including phototoxicity, pigmentary changes, crusting or scaling, and scar formation. All complications were mild, reversible, or both. When treatment responses were stratified by PWS morphology, PDT proved as effective as PDL in the treatment of pink flat lesions and more effective for purple flat lesions.

Although PDT has promise as a treatment approach, there are potential limitations. First, PWS vessels are believed to have a normal endothelial lining, which does not allow for the selective accumulation of photosensitizing agents within the target vessels. The use of antibody-labeled photosensitizers for selective targeting is futile without differential surface antigen expression on the endothelial cells in PWS vasculature. Another major drawback of PDT is the generalized photosensitivity that persists after therapy.<sup>117</sup> With the currently used photosensitizers, patients are counseled to avoid direct sunlight for up to 4 weeks after PDT treatment.<sup>123</sup> This inconvenience can be partially addressed by using photosensitizers with shorter circulation half-lives, such as benzoporphyrin derivative monoacid A, which remains photoactive for no more than 5 days.<sup>121</sup> Other limitations include the long length of treatment and the high costs of photosensitizers. Further study and careful planning of PDT regimens are required to address these issues.

The combination of PDL and PDT has been proposed to be synergistic. The suggested mechanism of action entails the administration of an initial, subtherapeutic PDT pulse to create injury to the vascular wall, after which irradiation with the PDL enhances the PDT-induced vascular damage. Because two methods of injury are used, lower radiant exposures can be employed for the PDT and PDL components, minimizing adverse effects such as scarring while inducing more extensive damage to the PWS vasculature. In a chick chorioallantoic membrane model, the combination of PDT and PDL treatment yielded significantly more vascular damage than either modality alone.<sup>124</sup>

In a clinical trial, Tournas et al<sup>121</sup> found a favorable dose-dependent treatment outcome using PDT with benzoporphyrin derivative monoacid ring A (576 nm) followed by 585-nm PDL irradiation. Treatment effects were evaluated by comparison of pretreatment and posttreatment photographs and chromametric measurements. Treatment efficacy appeared to improve with increased PDT radiant exposures. Overall, PDT-PDL combination therapy appears promising, although additional controlled clinical trials are needed to further evaluate the efficacy, safety, and advantages of the combined therapy.

### Angiogenesis inhibitors

It has been postulated that angiogenesis plays a critical role in limiting PWS treatment efficacy via posttreatment vascular repair of PWS vessels.<sup>24</sup> Initial interest in angiogenesis after selective laser injury was generated based on observations that acute vascular destruction does not necessarily result in PWS lightening.<sup>91</sup> Subsequent studies using laser speckle imaging on a rodent dorsal window chamber model demonstrated an initial shutdown in blood flow followed by reperfusion and vascular remodeling.<sup>125</sup> Serial laser speckle imaging monitoring of patients with PWS has also demonstrated the dynamic nature of the posttreatment blood flow response in the clinical setting.<sup>126</sup> Thus, it has been proposed that PDL treatment of vascular lesions could be enhanced by antiangiogenesis therapy after photocoagulation/PDT.<sup>24</sup>

**Imiquimod**—Imiquimod is a topically administered immune response modulator approved by the Food and Drug Administration (FDA) for the treatment of external genital warts, superficial basal cell carcinoma, and actinic keratosis.<sup>127</sup> As such, it is widely commercially

available and its favorable safety profile is well documented.<sup>127</sup> Imiquimod has been proposed to play a role in the inhibition of angiogenesis via: (1) activation of toll-like receptor 7, which induces the antiangiogenic cytokines interferon-alpha, interleukin-10, interleukin-12, and tissue inhibitors of metalloproteinases; and (2) inhibition of proangiogenic factors such as matrix metalloproteinases.<sup>128,129</sup> It has been successfully used for the treatment of vascular proliferative lesions such as infantile hemangiomas, pyogenic granulomas, Kaposi sarcoma, and hemangiosarcomas.<sup>128,130–133</sup>

Preliminary data from Tremaine et al<sup>134</sup> suggest that imiquimod antiangiogenesis therapy may enhance the treatment efficacy for PWS when used in conjunction with selective photothermolysis. In all, 24 healthy subjects with PWS were treated with PDL and then randomized to apply posttreatment placebo or 5% imiquimod cream 3 times a week for 8 weeks. Chromametric measurements taken at baseline were compared with measurements taken 8 weeks post-treatment. In comparison with PDL and placebo, PDL and imiquimod sites showed a statistically significant reduction in erythema and color improvement. Two patients developed minor erythema and crusting in the treatment area, but no other adverse effects were noted. After a brief rest period (1–4 weeks), imiquimod dosing was resumed without sequelae.

**Rapamycin**—Rapamycin (RPM), an inhibitor of mammalian target of RPM (mTOR), is a naturally occurring macrolide antibiotic that has been approved by the FDA for use as an immunosuppressant in organ transplant recipients and as a coronary stent coating to prevent restenosis.<sup>135,136</sup> In addition, RPM has antiangiogenesis properties that appear to be related to a decrease in both vascular endothelial growth factor production and responsiveness of endothelial cells to vascular endothelial growth factor.<sup>137</sup> Moreover, mTOR is known to be a downstream target of RAC-alpha serine/threonine-protein kinase (Akt1), the overexpression of which in endothelial cells causes cutaneous vascular malformations in mice.<sup>138</sup> RPM inhibits Akt1-induced pathological angiogenesis, thereby restoring normal-appearing vascular morphology.<sup>139</sup> In the eye, RPM reduces neovascularization in both laser-induced choroidal neovascularization and hypoxia-induced retinopathy of prematurity.<sup>140</sup>

In the skin, studies have suggested that RPM is promising in the treatment of vascular lesions when used in combination with laser therapy. In 2010, Jia et al<sup>25</sup> treated subdermal blood vessels in a rodent dorsal window model with laser alone versus topical RPM for 14 days after laser therapy, evaluating photocoagulation and reperfusion with color digital photography and laser speckle imaging. Whereas 23 of 24 (96%) treated blood vessels reperfused within 14 days in the group treated with laser alone, the overall reperfusion rate was only 36% in the group treated with varying concentrations of RPM. The reperfusion rate was not directly proportional to the RPM concentration.

Another study by Loewe et al<sup>141</sup> found robust expression of the proliferation marker Ki-67 and the stem cell marker nestin in dermal endothelial cells of PDL-irradiated skin. RPM administration reduced Ki-67 and nestin expression in dermal endothelial cells and increased PDL-induced destruction of dermal vessels. Although further studies are required, the use of

RPM after PDL exposure may be a promising new approach to improve PWS laser treatment outcomes.

### Hemodynamic alterations in PWS vasculature

Most approaches to optimizing selective photo-thermolysis of PWS vasculature have focused on ways to bring more light to the papillary and upper reticular dermis rather than on ways to bring more blood to the available light. Recently, several articles were published on the idea of perioperatively altering the hemodynamics of PWS vasculature so as to increase susceptibility to photoinduced damage.<sup>142–144</sup> The approach is based on the incongruence between the typical pulse durations used for PWS laser therapy and the thermal relaxation times of PDL-resistant PWS vasculature.<sup>142</sup> The venules in mild red or faint PWS (which predominate in infants and young children) and in laser-treated patients who have reached a therapeutic plateau have an average diameter of 10 to 30  $\mu\text{m}$ <sup>33</sup>. Most PDLs use 0.5- to 1.5-millisecond pulse durations, which exceed the thermal relaxation time of this category blood vessels.<sup>89</sup> Consequently, the target vessels are difficult to photocoagulate by selective photothermolysis because the volumetric heat production is insufficient to adequately heat the entire vessel wall.

One possible approach to increasing the diameter and thermal mass of small venules is to induce vessel dilation through hemostasis by temporarily obstructing venous blood flow via a pressure cuff placed on the proximal arm.<sup>142</sup> In several studies, it was demonstrated that low hypobaric (vacuum) pressures (between 17–51 kPa or 5–15 in Hg) applied for only a few (5–15) seconds before 585-nm PDL irradiation were sufficient to induce more intense purpura on the forearm of normal-appearing (Fig 4, A) and PWS (Fig 4, B) skin compared to control skin that underwent irradiation at the same settings but at atmospheric pressure.<sup>144</sup> Based on visible reflectance spectrometry and a diffusion approximation model,<sup>142</sup> it was estimated that approximately 35% less radiant exposure would be required to induce the same degree of purpura 3 days after laser exposure on subjects with normal-appearing skin. Most importantly, noticeable blanching of PWS skin, as quantified by visible reflectance spectrometry, was achieved 7 months after laser exposure to single laser pulses.

Although additional work is required to further optimize the modality, several recent clinical studies have underscored the potential role of local hypobaric pressure in PWS treatment optimization. For example, a pilot study with 11 patients with PWS refractory to PDL treatment revealed that hypobaric pressure application improved the treatment efficacy of the 595-nm PDL in approximately 50% of cases<sup>107</sup>. As addressed previously,<sup>142,144</sup> the authors observed that in some cases lower radiant exposures were sufficient to achieve blanching in otherwise PDL-resistant PWS.

### Site-specific pharmaco-laser therapy

SSPLT is a development-stage treatment modality that was designed on the basis of endovascular laser-tissue interactions in incompletely photocoagulated vasculature, which is thought to be responsible for therapeutic recalcitrance.<sup>24,145–147</sup> The laser-tissue interactions in these blood vessels are characterized by a photothermal response (thermal coagulation of blood)<sup>148,149</sup> and a hemodynamic response (thrombosis followed by fibrinolysis).<sup>146,147,150</sup>

The photo-thermal response is considered a static component, as thermal coagula do not expand after the laser pulse. Consequently, modulation of the extent of vaso-occlusion through the photothermal response is difficult.<sup>151</sup> In contrast, the hemodynamic response constitutes a highly dynamic process of thrombus growth and breakdown that can be modulated pharmacologically.<sup>151</sup>

The aim of SSPLT is to pharmacologically manipulate the hemodynamic response so as to cause complete occlusion of targeted vascular lumen that would otherwise only be partially photocoagulated. Complete occlusion has been associated with complete lesional clearance.<sup>24</sup> The procedure is detailed in Fig 5.

There are numerous classes of pharmaceuticals that modulate the hemodynamic response via induction of hyperthrombosis (eg, platelet activators, coagulation agonists) and deterrence of fibrinolysis (eg, plasmin inhibitors). Because such drugs may produce undesirable adverse effects, the pharmaceuticals are to be encapsulated in a thermosensitive liposomal drug delivery system and specifically targeted to PDL-irradiated vasculature. Liposomes are nanoscopic fat droplets that can encapsulate water-soluble and lipophilic drugs. Moreover, liposomal encapsulation restricts the biological activity of the drugs until they are released from the liposomes. Drug release can be systematically triggered via thermal, oxidative, enzymatic, or chemical processes.

The liposomes for SSPLT are selectively targeted to the thrombus (ie, via antibodies specific only to receptors on activated platelets involved in thrombosis) (Fig 5, step 2). Once the liposomes have accumulated in the thrombus, drug release will be triggered by local generation of heat using a heating pad or near infrared light (Fig 5, step 3). This will lead to site-specific hyperthrombosis and complete occlusion of the target vasculature (Fig 5, step 4), effecting the removal of blood vessels that would have otherwise remained partially patent. SSPLT may be combined with immunomodulatory and/or antiangiogenic modalities as described above to further modulate the chronic responses to laser therapy.<sup>24</sup>

Currently, the prothrombotic and antifibrinolytic liposomal formulations have been developed and characterized *in vitro*<sup>152</sup> and will be tested *in vivo* before the end of 2011. Once proof of concept has been established as to their targeting specificity and pharmacodynamics, and toxicological testing has been completed, clinical phase II trials will be initiated.

## CONCLUSION

Despite innovations in various laser techniques, our retrospective analysis shows that the number of patients with PWS who do not achieve complete lesion removal with current treatment modalities remains substantial. Consequently, the exploration and implementation of alternative therapies is necessary for improvement of therapeutic efficacy. Treatment failure has largely been attributed to lesional variation, posttreatment angiogenesis, and limitations in optical penetration depth. Several promising approaches have been presented that may improve therapeutic efficacy, including PDT, immunomodulation, antiangiogenesis therapy, hypobaric pressure devices, and SSPLT.

## Supplementary Material

Refer to Web version on PubMed Central for supplementary material.

## Acknowledgments

Dr Aguilar was funded by grant HD042057 from the National Institutes of Health (NIH). Dr Kelly was funded by the NIH (AR51443 and HD065536), the American Society for Laser Medicine and Surgery, and a research grant from Graceway Pharmaceuticals.

Work was in part performed at Centro de Investigación y Estudios Avanzados del Instituto Politécnico Nacional, campus Querétaro, México, during sabbatical leave (Dr Aguilar).

## Abbreviations used

<b>FDA</b>	Food and Drug Administration
<b>IPL</b>	intense pulsed light
<b>Nd:YAG</b>	neodymium:yttrium-aluminum-garnet
<b>PDL</b>	pulsed dye laser
<b>PDT</b>	photodynamic therapy
<b>PWS</b>	port wine stains
<b>RPM</b>	rapamycin
<b>SSPLT</b>	site-specific pharmacolaser therapy

## REFERENCES

- Schneider BV, Mitsuhashi Y, Schnyder UW. Ultrastructural observations in port wine stains. *Arch Dermatol Res.* 1988; 280:338–345. [PubMed: 3190266]
- Barsky SH, Rosen S, Geer DE, Noe JM. The nature and evolution of port wine stains: a computer-assisted study. *J Invest Dermatol.* 1980; 74:154–157. [PubMed: 7359006]
- Goldman, MP.; Fitzpatrick, RE. *Cutaneous laser surgery: the art and science of selective photothermolysis.* St Louis, MO: Mosby; 1994.
- Geronemus RG, Ashinoff R. The medical necessity of evaluation and treatment of port-wine stains. *J Dermatol Surg Oncol.* 1991; 17:76–79. [PubMed: 1991884]
- Enjolras O, Mulliken JB. The current management of vascular birthmarks. *Pediatr Dermatol.* 1993; 10:311–313. [PubMed: 8302734]
- Lanigan SW, Cotterill JA. Psychological disabilities amongst patients with port wine stains. *Br J Dermatol.* 1989; 121:209–215. [PubMed: 2775645]
- Malm M, Carlberg M. Port-wine stain—a surgical and psychological problem. *Ann Plast Surg.* 1988; 20:512–516. [PubMed: 3389703]
- Welch, AJ.; Van Gemert, MJC. *Optical-thermal response of laser-irradiated tissue.* New York: Plenum Publishing Corp; 1995.
- Fiskerstrand EJ, Svaasand LO, Kopstad G, Ryggen K, Aase S. Photothermally induced vessel-wall necrosis after pulsed dye laser treatment: lack of response in port-wine stains with small sized or deeply located vessels. *J Invest Dermatol.* 1996; 107:671–675. [PubMed: 8875947]
- Greve B, Raulin C. Prospective study of port wine stain treatment with dye laser: comparison of two wavelengths (585 nm vs 595 nm) and two pulse durations (0.5 milliseconds vs 20 milliseconds). *Lasers Surg Med.* 2004; 34:168–173. [PubMed: 15004830]

11. Hohenleutner U, Hilbert M, Wlotzke U, Landthaler M. Epidermal damage and limited coagulation depth with the flashlamp-pumped pulsed dye laser: a histochemical study. *J Invest Dermatol.* 1995; 104:798–802. [PubMed: 7738359]
12. Tan OT, Carney JM, Margolis R, Seki Y, Boll J, Anderson RR, et al. Histologic responses of port-wine stains treated by argon, carbon dioxide, and tunable dye lasers: a preliminary report. *Arch Dermatol.* 1986; 122:1016–1022. [PubMed: 3090945]
13. Verkruysse W, Lucassen GW, van Gemert MJ. Simulation of color of port wine stain skin and its dependence on skin variables. *Lasers Surg Med.* 1999; 25:131–139. [PubMed: 10455219]
14. Kelly KM, Nanda VS, Nelson JS. Treatment of port-wine stain birthmarks using the 1.5-msec pulsed dye laser at high fluences in conjunction with cryogen spray cooling. *Dermatol Surg.* 2002; 28:309–313. [PubMed: 11966787]
15. Tunnell JW, Chang DW, Johnston C, Torres JH, Patrick CW Jr, Miller MJ, et al. Effects of cryogen spray cooling and high radiant exposures on selective vascular injury during laser irradiation of human skin. *Arch Dermatol.* 2003; 139:743–750. [PubMed: 12810505]
16. Dai T, Pikkula BM, Tunnell JW, Chang DW, Anvari B. Thermal response of human skin epidermis to 595-nm laser irradiation at high incident dosages and long pulse durations in conjunction with cryogen spray cooling: an ex-vivo study. *Lasers Surg Med.* 2003; 33:16–24. [PubMed: 12866117]
17. Lucassen GW, Verkruysse W, Keijzer M, van Gemert MJ. Light distributions in a port wine stain model containing multiple cylindrical and curved blood vessels. *Lasers Surg Med.* 1996; 18:345–357. [PubMed: 8732573]
18. Fiskerstrand EJ, Svaasand LO, Kopstad G, Dalaker M, Norvang LT, Volden G. Laser treatment of port wine stains: therapeutic outcome in relation to morphological parameters. *Br J Dermatol.* 1996; 134:1039–1043. [PubMed: 8763421]
19. Pickering JW, van Gemert MJ. 585 nm For the laser treatment of port wine stains: a possible mechanism. *Lasers Surg Med.* 1991; 11:616–618. [PubMed: 1753856]
20. Verkruysse W, Pickering JW, Beek JF, Keijzer M, van Gemert MJ. Modeling the effect of wavelength on the pulsed dye laser treatment of port wine stains. *Appl Opt.* 1993; 32:393–398. [PubMed: 20802703]
21. van Gemert MJ, Smithies DJ, Verkruysse W, Milner TE, Nelson JS. Wavelengths for port wine stain laser treatment: influence of vessel radius and skin anatomy. *Phys Med Biol.* 1997; 42:41–50. [PubMed: 9015807]
22. Tan OT, Morrison P, Kurban AK. 585 nm For the treatment of port-wine stains. *Plast Reconstr Surg.* 1990; 86:1112–1117. [PubMed: 2243853]
23. Troilius A, Svendsen G, Ljunggren B. Ultrasound investigation of port wine stains. *Acta Derm Venereol.* 2000; 80:196–199. [PubMed: 10954211]
24. Heger M, Beek JF, Moldovan NI, van der Horst CM, van Gemert MJ. Towards optimization of selective photothermolysis: prothrombotic pharmaceutical agents as potential adjuvants in laser treatment of port wine stains; a theoretical study. *Thromb Haemost.* 2005; 93:242–256. [PubMed: 15711739]
25. Jia W, Sun V, Tran N, Choi B, Liu SW, Mihm MC Jr, et al. Long-term blood vessel removal with combined laser and topical rapamycin antiangiogenic therapy: implications for effective port wine stain treatment. *Lasers Surg Med.* 2010; 42:105–112. [PubMed: 20166161]
26. Morelli JG, Tan OT, Garden J, Margolis R, Seki Y, Boll J, et al. Tunable dye laser (577 nm) treatment of port wine stains. *Lasers Surg Med.* 1986; 6:94–99. [PubMed: 3959722]
27. Kauvar AN, Geronemus RG. Repetitive pulsed dye laser treatments improve persistent port-wine stains. *Dermatol Surg.* 1995; 21:515–521. [PubMed: 7773599]
28. Morelli JG, Weston WL, Huff JC, Yohn JJ. Initial lesion size as a predictive factor in determining the response of port-wine stains in children treated with the pulsed dye laser. *Arch Pediatr Adolesc Med.* 1995; 149:1142–1144. [PubMed: 7550819]
29. Renfro L, Geronemus RG. Anatomical differences of port-wine stains in response to treatment with the pulsed dye laser. *Arch Dermatol.* 1993; 129:182–188. [PubMed: 8434975]
30. Tan OT, Sherwood K, Gilchrist BA. Treatment of children with port-wine stains using the flashlamp-pulsed tunable dye laser. *N Engl J Med.* 1989; 320:416–421. [PubMed: 2913507]

31. Tan OT, Stafford TJ. Treatment of port-wine stains at 577 nm: clinical results. *Med Instrum.* 1987; 21:218–221. [PubMed: 3452742]
32. Garden JM, Polla LL, Tan OT. The treatment of port-wine stains by the pulsed dye laser: analysis of pulse duration and long-term therapy. *Arch Dermatol.* 1988; 124:889–896. [PubMed: 3377518]
33. Nguyen CM, Yohn JJ, Huff C, Weston WL, Morelli JG. Facial port wine stains in childhood: prediction of the rate of improvement as a function of the age of the patient, size and location of the port wine stain and the number of treatments with the pulsed dye (585 nm) laser. *Br J Dermatol.* 1998; 138:821–825. [PubMed: 9666828]
34. Reyes BA, Geronemus R. Treatment of port-wine stains during childhood with the flashlamp-pumped pulsed dye laser. *J Am Acad Dermatol.* 1990; 23:1142–1148. [PubMed: 2273116]
35. Achauer BM, Vander Kam VM, Miller SR. Clinical experience with the pulsed-dye laser in the treatment of capillary malformations (port-wine stains): a preliminary report. *Ann Plast Surg.* 1990; 25:344–352. [PubMed: 2256647]
36. Ashinoff R, Geronemus RG. Flashlamp-pumped pulsed dye laser for port-wine stains in infancy: earlier versus later treatment. *J Am Acad Dermatol.* 1991; 24:467–472. [PubMed: 2061448]
37. Goldman MP, Fitzpatrick RE, Ruiz-Esparza J. Treatment of port-wine stains (capillary malformation) with the flashlamp-pumped pulsed dye laser. *J Pediatr.* 1993; 122:71–77. [PubMed: 8419617]
38. Achauer BM, Vander Kam VM, Padilla JF III. Clinical experience with the tunable pulsed-dye laser (585 nm) in the treatment of capillary vascular malformations. *Plast Reconstr Surg.* 1993; 92:1233–1243. [PubMed: 8248398]
39. Alster TS, Wilson F. Treatment of port-wine stains with the flashlamp-pumped pulsed dye laser: extended clinical experience in children and adults. *Ann Plast Surg.* 1994; 32:478–484. [PubMed: 8060071]
40. Fitzpatrick RE, Lowe NJ, Goldman MP, Borden H, Behr KL, Ruiz-Esparza J. Flashlamp-pumped pulsed dye laser treatment of port-wine stains. *J Dermatol Surg Oncol.* 1994; 20:743–748. [PubMed: 7962935]
41. Taieb A, Touati L, Cony M, Leaute-Labreze C, Mortureux P, Renaud P, et al. Treatment of port-wine stains with the 585-nm flashlamp-pulsed tunable dye laser: a study of 74 patients. *Dermatology.* 1994; 188:276–281. [PubMed: 8193399]
42. Onizuka K, Tsuneda K, Shibata Y, Ito M, Sekine I. Efficacy of flashlamp-pumped pulsed dye laser therapy for port wine stains: clinical assessment and histopathological characteristics. *Br J Plast Surg.* 1995; 48:271–279. [PubMed: 7633763]
43. Troilius A, Ljunggren B. Reflectance spectrophotometry in the objective assessment of dye laser-treated port-wine stains. *Br J Dermatol.* 1995; 132:245–250. [PubMed: 7888361]
44. Goh CL. Treatment response of port-wine stains with the flashlamp-pulsed dye laser in the National Skin Center: a report of 36 patients. *Ann Acad Med Singapore.* 1996; 25:536–540. [PubMed: 8893925]
45. Orten SS, Waner M, Flock S, Roberson PK, Kincannon J. Port-wine stains: an assessment of 5 years of treatment. *Arch Otolaryngol Head Neck Surg.* 1996; 122:1174–1179. [PubMed: 8906051]
46. van der Horst CM, Koster PH, de Borgie CA, Bossuyt PM, van Gemert MJ. Effect of the timing of treatment of port-wine stains with the flash-lamp-pumped pulsed-dye laser. *N Engl J Med.* 1998; 338:1028–1033. [PubMed: 9535667]
47. Sommer S, Sheehan-Dare RA. Pulsed dye laser treatment of port-wine stains in pigmented skin. *J Am Acad Dermatol.* 2000; 42:667–671. [PubMed: 10727315]
48. Goh CL. Flashlamp-pumped pulsed dye laser (585 nm) for the treatment of portwine stains—a study of treatment outcome in 94 Asian patients in Singapore. *Singapore Med J.* 2000; 41:24–28. [PubMed: 10783676]
49. Namba Y, Mae O, Ao M. The treatment of port wine stains with a dye laser: a study of 644 patients. *Scand J Plast Reconstr Surg Hand Surg.* 2001; 35:197–202. [PubMed: 11484530]
50. Woo WK, Handley JM. Does fluence matter in the laser treatment of port-wine stains? *Clin Exp Dermatol.* 2003; 28:556–557. [PubMed: 12950354]

51. Huikeshoven M, Koster PH, de Borgie CA, Beek JF, van Gemert MJ, van der Horst CM. Redarkening of port-wine stains 10 years after pulsed-dye-laser treatment. *N Engl J Med*. 2007; 356:1235–1240. [PubMed: 17377161]
52. Tan OT, Murray S, Kurban AK. Action spectrum of vascular specific injury using pulsed irradiation. *J Invest Dermatol*. 1989; 92:868–871. [PubMed: 2723451]
53. Verkruysse W, Lucassen GW, de Boer JF, Smithies DJ, Nelson JS, van Gemert MJ. Modeling light distributions of homogeneous versus discrete absorbers in light irradiated turbid media. *Phys Med Biol*. 1997; 42:51–65. [PubMed: 9015808]
54. Geronemus RG, Quintana AT, Lou WW, Kauvar AN. High-fluence modified pulsed dye laser photocoagulation with dynamic cooling of port-wine stains in infancy. *Arch Dermatol*. 2000; 136:942–943. [PubMed: 10891010]
55. Asahina A, Watanabe T, Kishi A, Hattori N, Shirai A, Kagami S, et al. Evaluation of the treatment of port-wine stains with the 595-nm long pulsed dye laser: a large prospective study in adult Japanese patients. *J Am Acad Dermatol*. 2006; 54:487–493. [PubMed: 16488301]
56. Laube S, Taibjee S, Lanigan SW. Treatment of resistant port wine stains with the V beam pulsed dye laser. *Lasers Surg Med*. 2003; 33:282–287. [PubMed: 14677155]
57. Kono T, Sakurai H, Takeuchi M, Yamaki T, Soejima K, Groff WF, et al. Treatment of resistant port-wine stains with a variable-pulse pulsed dye laser. *Dermatol Surg*. 2007; 33:951–956. [PubMed: 17661938]
58. Woo SH, Ahn HH, Kim SN, Kye YC. Treatment of vascular skin lesions with the variable-pulse 595 nm pulsed dye laser. *Dermatol Surg*. 2006; 32:41–48. [PubMed: 16393597]
59. Jasim ZF, Handley JM. Treatment of pulsed dye laser-resistant port wine stain birthmarks. *J Am Acad Dermatol*. 2007; 57:677–682. [PubMed: 17658196]
60. Babilas P, Schreml S, Eames T, Hohenleutner U, Szeimies RM, Landthaler M. Split-face comparison of intense pulsed light with short- and long-pulsed dye lasers for the treatment of port-wine stains. *Lasers Surg Med*. 2010; 42:720–727. [PubMed: 20886506]
61. Bernstein EF. Treatment of a resistant port-wine stain with a new variable pulse-duration pulsed-dye laser. *J Cosmet Dermatol*. 2008; 7:139–142. [PubMed: 18482019]
62. Woo WK, Jasim ZF, Handley JM. Evaluating the efficacy of treatment of resistant port-wine stains with variable-pulse 595-nm pulsed dye and 532-nm Nd:YAG lasers. *Dermatol Surg*. 2004; 30:158–162. [PubMed: 14756643]
63. Kono T, Groff WF, Sakurai H, Takeuchi M, Yamaki T, Soejima K, et al. Evaluation of fluence and pulse-duration on purpuric threshold using an extended pulse pulsed-dye laser in the treatment of port wine stains. *J Dermatol*. 2006; 33:473–476. [PubMed: 16848819]
64. Cole PD, Sonabend ML, Levy ML. Laser treatment of pediatric vascular lesions. *Semin Plast Surg*. 2007; 21:159–166. [PubMed: 20567667]
65. Li L, Kono T, Groff WF, Chan HH, Kitazawa Y, Nozaki M. Comparison study of a long-pulse pulsed dye laser and a long-pulse pulsed alexandrite laser in the treatment of port wine stains. *J Cosmet Laser Ther*. 2008; 10:12–15. [PubMed: 18330793]
66. Yang MU, Yaroslavsky AN, Farinelli WA, Flotte TJ, Rius-Diaz F, Tsao SS, et al. Long-pulsed neodymium:yttrium-aluminum-garnet laser treatment for port-wine stains. *J Am Acad Dermatol*. 2005; 52:480–490. [PubMed: 15761427]
67. Alster TS, Tanzi EL. Combined 595-nm and 1,064-nm laser irradiation of recalcitrant and hypertrophic port-wine stains in children and adults. *Dermatol Surg*. 2009; 35:914–919. [PubMed: 19397657]
68. Whang KK, Byun JY, Kim SH. A dual-wavelength approach with 585-nm pulsed-dye laser and 800-nm diode laser for treatment-resistant port-wine stains. *Clin Exp Dermatol*. 2009; 34:e436–e437. [PubMed: 19747305]
69. Izikson L, Nelson JS, Anderson RR. Treatment of hypertrophic and resistant port wine stains with a 755 nm laser: a case series of 20 patients. *Lasers Surg Med*. 2009; 41:427–432. [PubMed: 19588532]
70. Izikson L, Anderson RR. Treatment endpoints for resistant port wine stains with a 755 nm laser. *J Cosmet Laser Ther*. 2009; 11:52–55. [PubMed: 19012069]

71. Dummer R, Graf P, Greif C, Burg G. Treatment of vascular lesions using the VersaPulse variable pulse width frequency doubled neodymium:YAGlaser. *Dermatology*. 1998; 197:158–161. [PubMed: 9732166]
72. Chan HH, Chan E, Kono T, Ying SY, Wai-Sun H. The use of variable pulse width frequency doubled Nd:YAG 532 nm laser in the treatment of port-wine stain in Chinese patients. *Dermatol Surg*. 2000; 26:657–661. [PubMed: 10886274]
73. Pence B, Aybey B, Ergenekon G. Outcomes of 532 nm frequency-doubled Nd:YAG laser use in the treatment of port-wine stains. *Dermatol Surg*. 2005; 31:509–517. [PubMed: 15962732]
74. Ho WS, Ying SY, Chan PC, Chan HH. Treatment of port wine stains with intense pulsed light: a prospective study. *Dermatol Surg*. 2004; 30:887–891. [PubMed: 15171767]
75. Bjerring P, Christiansen K, Troilius A. Intense pulsed light source for the treatment of dye laser resistant port-wine stains. *J Cosmet Laser Ther*. 2003; 5:7–13. [PubMed: 12745594]
76. Reynolds N, Exley J, Hills S, Falder S, Duff C, Kenealy J. The role of the Lumina intense pulsed light system in the treatment of port wine stains—a case controlled study. *Br J Plast Surg*. 2005; 58:968–980. [PubMed: 16043156]
77. Ozdemir M, Engin B, Mevlitoglu I. Treatment of facial port-wine stains with intense pulsed light: a prospective study. *J Cosmet Dermatol*. 2008; 7:127–131. [PubMed: 18482016]
78. Li G, Lin T, Wu Q, Zhou Z, Gold MH. Clinical analysis of port wine stains treated by intense pulsed light. *J Cosmet Laser Ther*. 2010; 12:2–6. [PubMed: 20085450]
79. Adatto MA, Luc-Levy J, Mordon S. Efficacy of a novel intense pulsed light system for the treatment of port wine stains. *J Cosmet Laser Ther*. 2010; 12:54–60. [PubMed: 20331340]
80. Raulin C, Schroeter CA, Weiss RA, Keiner M, Werner S. Treatment of port-wine stains with a noncoherent pulsed light source: a retrospective study. *Arch Dermatol*. 1999; 135:679–683. [PubMed: 10376695]
81. Faurschou A, Togsverd-Bo K, Zachariae C, Haedersdal M. Pulsed dye laser vs intense pulsed light for port-wine stains: a randomized side-by-side trial with blinded response evaluation. *Br J Dermatol*. 2009; 160:359–364. [PubMed: 19120324]
82. Bencini PL. The multilayer technique: a new and fast approach for flashlamp-pumped pulsed (FLPP) dye laser treatment of port-wine stains (preliminary reports). *Dermatol Surg*. 1999; 25:786–789. [PubMed: 10594580]
83. Lorenz S, Brunnerberg S, Landthaler M, Hohenleutner U. Regarding the multilayer technique for treatment of PWS. *Dermatol Surg*. 2001; 27:90. [PubMed: 11231257]
84. Tanghetti E, Sherr EA, Sierra R, Mirkov M. The effects of pulse dye laser double-pass treatment intervals on depth of vessel coagulation. *Lasers Surg Med*. 2006; 38:16–21. [PubMed: 16444693]
85. Rajaratnam R, Laughlin SA, Dudley D. Pulsed dye laser double-pass treatment of patients with resistant capillary malformations. *Lasers Med Sci*. 2011; 26:487–492. [PubMed: 21476044]
86. Nelson JS, Milner TE, Anvari B, Tanenbaum BS, Svaasand LO, Kimel S. Dynamic epidermal cooling in conjunction with laser-induced photothermolysis of port wine stain blood vessels. *Lasers Surg Med*. 1996; 19:224–229. [PubMed: 8887927]
87. Fiskerstran EJ, Ryggen K, Norvang LT, Svaasand LO. Clinical effects of dynamic cooling during pulsed laser treatment of port-wine stains. *Lasers Med Sci*. 1997; 12:320–327. [PubMed: 20803271]
88. Chiu CH, Chan HH, Ho WS, Yeung CK, Nelson JS. Prospective study of pulsed dye laser in conjunction with cryogen spray cooling for treatment of port wine stains in Chinese patients. *Dermatol Surg*. 2003; 29:909–915. [PubMed: 12930331]
89. Bernstein EF, Brown DB. Efficacy of the 1.5 millisecond pulse-duration, 585 nm, pulsed-dye laser for treating port-wine stains. *Lasers Surg Med*. 2005; 36:341–346. [PubMed: 15898098]
90. Sharma VK, Khandpur S. Efficacy of pulsed dye laser in facial port-wine stains in Indian patients. *Dermatol Surg*. 2007; 33:560–566. [PubMed: 17451578]
91. Kelly KM, Choi B, McFarlane S, Motosue A, Jung B, Khan MH, et al. Description and analysis of treatments for port-wine stain birthmarks. *Arch Facial Plast Surg*. 2005; 7:287–294. [PubMed: 16172335]
92. Greve B, Hammes S, Raulin C. The effect of cold air cooling on 585 nm pulsed dye laser treatment of port-wine stains. *Dermatol Surg*. 2001; 27:633–636. [PubMed: 11442613]

93. Chapas AM, Eickhorst K, Geronemus RG. Efficacy of early treatment of facial port wine stains in newborns: a review of 49 cases. *Lasers Surg Med.* 2007; 39:563–568. [PubMed: 17868100]
94. Tomson N, Lim SP, Abdullah A, Lanigan SW. The treatment of port-wine stains with the pulsed-dye laser at 2-week and 6-week intervals: a comparative study. *Br J Dermatol.* 2006; 154:676–679. [PubMed: 16536811]
95. Bernstein EF. High-energy 595 nm pulsed dye laser improves refractory port-wine stains. *Dermatol Surg.* 2006; 32:26–33. [PubMed: 16393595]
96. Liu H, Dang Y, Chai X, Wang Z, Ma L, Ren Q. Treatment of port-wine stains with the 595-nm pulsed dye laser: a pilot study in Chinese patients. *Clin Exp Dermatol.* 2007; 32:646–649. [PubMed: 17953633]
97. Scherer K, Lorenz S, Wimmershoff M, Landthaler M, Hohenleutner U. Both the flashlamp-pumped dye laser and the long-pulsed tunable dye laser can improve results in port-wine stain therapy. *Br J Dermatol.* 2001; 145:79–84. [PubMed: 11453911]
98. Chang CJ, Kelly KM, Van Gemert MJ, Nelson JS. Comparing the effectiveness of 585-nm vs 595-nm wavelength pulsed dye laser treatment of port wine stains in conjunction with cryogen spray cooling. *Lasers Surg Med.* 2002; 31:352–358. [PubMed: 12430153]
99. Yung A, Sheehan-Dare R. A comparative study of a 595-nm with a 585-nm pulsed dye laser in refractory port wine stains. *Br J Dermatol.* 2005; 153:601–606. [PubMed: 16120150]
100. Watanabe S. Basics of laser application to dermatology. *Arch Dermatol Res.* 2008; 300(Suppl):S21–S30. [PubMed: 17962966]
101. Dover JS, Geronemus R, Stern RS, O'Hare D, Arndt KA. Dye laser treatment of port-wine stains: comparison of the continuous-wave dye laser with a robotized scanning device and the pulsed dye laser. *J Am Acad Dermatol.* 1995; 32:237–240. [PubMed: 7829709]
102. Edstrom DW, Hedblad MA, Ros AM. Flashlamp pulsed dye laser and argon-pumped dye laser in the treatment of port-wine stains: a clinical and histological comparison. *Br J Dermatol.* 2002; 146:285–289. [PubMed: 11903241]
103. Ho WS, Chan HH, Ying SY, Chan PC. Laser treatment of congenital facial port-wine stains: long-term efficacy and complication in Chinese patients. *Lasers Surg Med.* 2002; 30:44–47. [PubMed: 11857603]
104. Lorenz S, Scherer K, Wimmershoff MB, Landthaler M, Hohenleutner U. Variable pulse frequency-doubled Nd:YAG laser versus flashlamp-pumped pulsed dye laser in the treatment of port wine stains. *Acta Derm Venereol.* 2003; 83:210–213. [PubMed: 12816158]
105. Sheehan-Dare RA, Cotterill JA. Copper vapor laser (578 nm) and flashlamp-pumped pulsed tunable dye laser (585 nm) treatment of port wine stains: results of a comparative study using test sites. *Br J Dermatol.* 1994; 130:478–482. [PubMed: 8186113]
106. Borges da Costa J, Boixeda P, Moreno C, Santiago J. Treatment of resistant port-wine stains with a pulsed dual wavelength 595 and 1064 nm laser: a histochemical evaluation of the vessel wall destruction and selectivity. *Photomed Laser Surg.* 2009; 27:599–605. [PubMed: 19558312]
107. Kautz G, Kautz I, Segal J, Zehren S. Treatment of resistant port wine stains (PWS) with pulsed dye laser and non-contact vacuum: a pilot study. *Lasers Med Sci.* 2010; 25:525–529. [PubMed: 20013138]
108. Chang CJ, Hsiao YC, Mihm MC Jr, Nelson JS. Pilot study examining the combined use of pulsed dye laser and topical Imiquimod versus laser alone for treatment of port wine stain birthmarks. *Lasers Surg Med.* 2008; 40:605–10. [PubMed: 18951427]
109. Kono T, Frederick Groff W, Chan HH, Sakurai H, Yamaki T. Long-pulsed neodymium:yttrium-aluminum-garnet laser treatment for hypertrophic port-wine stains on the lips. *J Cosmet Laser Ther.* 2009; 11:11–13. [PubMed: 18830868]
110. Civas E, Koc E, Aksoy B, Aksoy HM. Clinical experience in the treatment of different vascular lesions using a neodymium-doped yttrium aluminum garnet laser. *Dermatol Surg.* 2009; 35:1933–1941. [PubMed: 19889008]
111. Chowdhury MM, Harris S, Lanigan SW. Potassium titanyl phosphate laser treatment of resistant port-wine stains. *Br J Dermatol.* 2001; 144:814–817. [PubMed: 11298542]

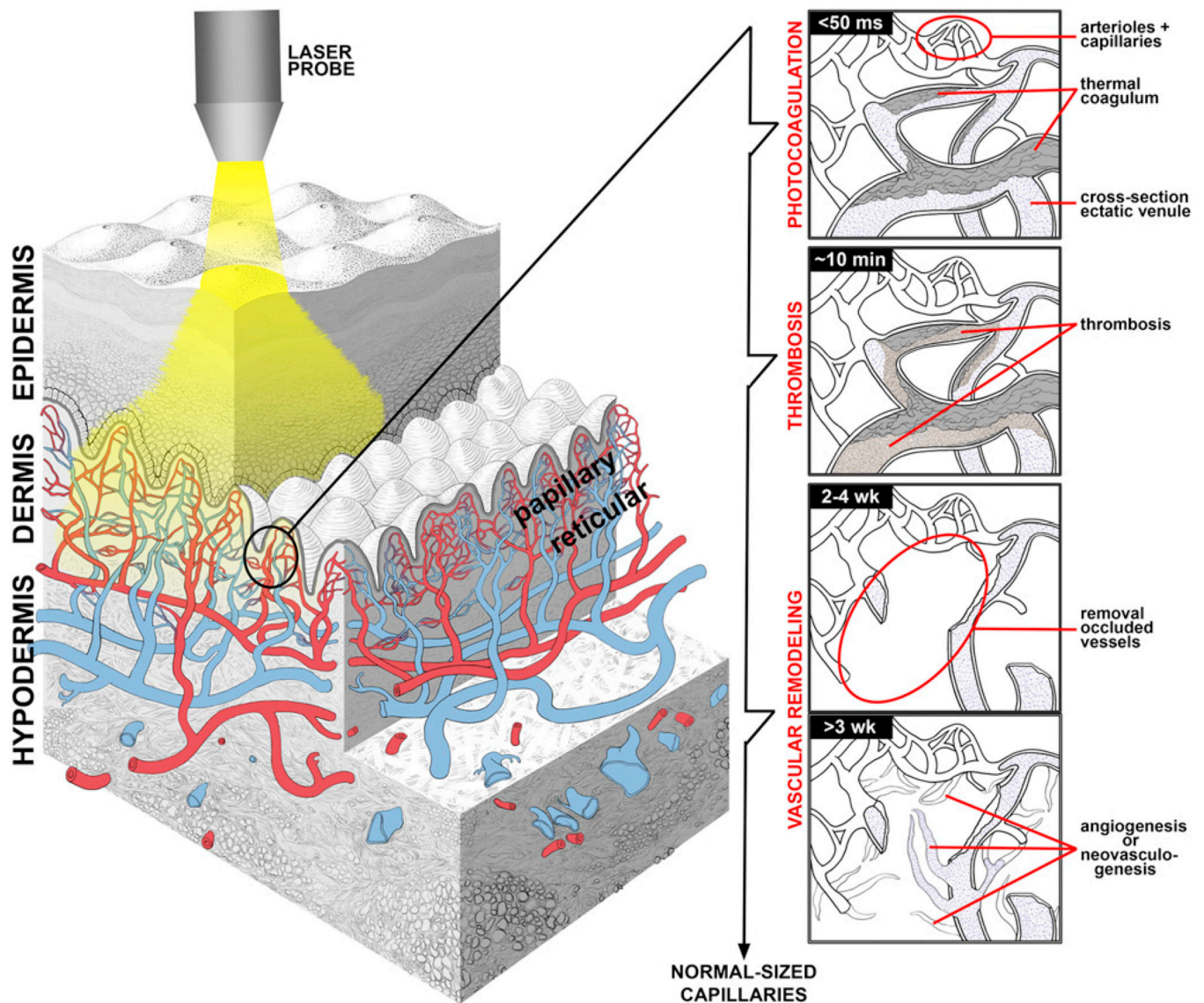
112. Ahcan U, Zorman P, Recek D, Ralca S, Majaron B. Port wine stain treatment with a dual-wavelength Nd:YAG laser and cryogen spray cooling: a pilot study. *Lasers Surg Med.* 2004; 34:164–167. [PubMed: 15004829]
113. Orenstein A, Nelson JS, Liaw LH, Kaplan R, Kimel S, Berns MW. Photochemotherapy of hypervascular dermal lesions: a possible alternative to photothermal therapy? *Lasers Surg Med.* 1990; 10:334–343. [PubMed: 2144032]
114. Ying G, Junheng L, Huanyan S. Clinical application of copper vapor laser in PDT for fifty cases of PWS. *Chin J Laser Med Surg.* 1994; 3:215–217.
115. Lin XX, Wang W, Wu SF, Yang C, Chang TS. Treatment of capillary vascular malformation (port-wine stains) with photochemotherapy. *Plast Reconstr Surg.* 1997; 99:1826–1830. [PubMed: 9180705]
116. Qin ZP, Li KL, Ren L, Liu XJ. Photodynamic therapy of port wine stains—a report of 238 cases. *Photodiagnosis Photodyn Ther.* 2007; 4:53–59. [PubMed: 25047192]
117. Lu YG, Wu JJ, Yang YD, Yang HZ, He Y. Photodynamic therapy of port-wine stains. *J Dermatolog Treat.* 2010; 21:240–244. [PubMed: 19722122]
118. Wang Y, Gu Y, Liao X, Chen R, Ding H. Fluorescence monitoring of a photosensitizer and prediction of the therapeutic effect of photodynamic therapy for port wine stains. *Exp Biol Med (Maywood).* 2010; 235:175–180. [PubMed: 20404032]
119. Evans AV, Robson A, Barlow RJ, Kurwa HA. Treatment of port wine stains with photodynamic therapy, using pulsed dye laser as a light source, compared with pulsed dye laser alone: a pilot study. *Lasers Surg Med.* 2005; 36:266–269. [PubMed: 15786480]
120. Yuan KH, Li Q, Yu WL, Zeng D, Zhang C, Huang Z. Comparison of photodynamic therapy and pulsed dye laser in patients with port wine stain birthmarks: a retrospective analysis. *Photodiagnosis Photodyn Ther.* 2008; 5:50–57. [PubMed: 19356637]
121. Tournas JA, Lai J, Truitt A, Huang YC, Osann KE, Choi B, et al. Combined benzoporphyrin derivative monoacid ring photodynamic therapy and pulsed dye laser for port wine stain birthmarks. *Photodiagnosis Photodyn Ther.* 2009; 6:195–199. [PubMed: 19932451]
122. Krammer B. Vascular effects of photodynamic therapy. *Anti-cancer Res.* 2001; 21:4271–4277.
123. Yuan KH, Li Q, Yu WL, Huang Z. Photodynamic therapy in treatment of port wine stain birthmarks—recent progress. *Photodiagnosis Photodyn Ther.* 2009; 6:189–194. [PubMed: 19932450]
124. Kelly KM, Kimel S, Smith T, Stacy A, Hammer-Wilson MJ, Svaasand LO, et al. Combined photodynamic and photothermal induced injury enhances damage to in vivo model blood vessels. *Lasers Surg Med.* 2004; 34:407–413. [PubMed: 15216534]
125. Choi B, Jia W, Channual J, Kelly KM, Lotfi J. The importance of long-term monitoring to evaluate the microvascular response to light-based therapies. *J Invest Dermatol.* 2008; 128:485–488. [PubMed: 17657245]
126. Huang YC, Tran N, Shumaker PR, Kelly K, Ross EV, Nelson JS, et al. Blood flow dynamics after laser therapy of port wine stain birthmarks. *Lasers Surg Med.* 2009; 41:563–571. [PubMed: 19731304]
127. Wagstaff AJ, Perry CM. Topical imiquimod: a review of its use in the management of anogenital warts, actinic keratoses, basal cell carcinoma and other skin lesions. *Drugs.* 2007; 67:2187–2210. [PubMed: 17927284]
128. Li VW, Li WW, Talcott KE, Zhai AW. Imiquimod as an antiangiogenic agent. *J Drugs Dermatol.* 2005; 4:708–717. [PubMed: 16302556]
129. Majewski S, Marczak M, Mlynarczyk B, Benninghoff B, Jablonska S. Imiquimod is a strong inhibitor of tumor cell-induced angiogenesis. *Int J Dermatol.* 2005; 44:14–19. [PubMed: 15663652]
130. Celestin Schartz NE, Chevret S, Paz C, Kerob D, Verola O, Morel P, et al. Imiquimod 5% cream for treatment of HIV-negative Kaposi's sarcoma skin lesions: a phase I to II, open-label trial in 17 patients. *J Am Acad Dermatol.* 2008; 58:585–591. [PubMed: 18068265]
131. Marra DE, Haynes HA, Li VW. Antiangiogenic treatment of pyogenic granuloma with imiquimod 1. *J Am Acad Dermatol.* 2004; 50:P57.

132. Welsh O, Olazarán Z, Gómez M, Salas J, Berman B. Treatment of infantile hemangiomas with short-term application of imiquimod 5% cream. *J Am Acad Dermatol.* 2004; 51:639–642. [PubMed: 15389206]
133. Hazen PG, Carney JF, Engstrom CW, Turgeon KL, Reep MD, Tanphaichitr A. Proliferating hemangioma of infancy: successful treatment with topical 5% imiquimod cream. *Pediatr Dermatol.* 2005; 22:254–256. [PubMed: 15916578]
134. Tremaine AM, Armstrong J, Huang Y-C, Elkeeb L, Ortiz A, Harris R, et al. Enhanced port-wine stain lightening achieved with combined treatment of selective photothermolysis and imiquimod. *J Am Acad Dermatol.* Published online January 16, 2012.
135. Saunders RN, Metcalfe MS, Nicholson ML. Rapamycin in transplantation: a review of the evidence. *Kidney Int.* 2001; 59:3–16. [PubMed: 11135052]
136. Morice MC, Serruys PW, Sousa JE, Fajadet J, Ban Hayashi E, Perin M, et al. A randomized comparison of a sirolimus-eluting stent with a standard stent for coronary revascularization. *N Engl J Med.* 2002; 346:1773–1780. [PubMed: 12050336]
137. Guba M, von Breitenbuch P, Steinbauer M, Koehl G, Flegel S, Hornung M, et al. Rapamycin inhibits primary and metastatic tumor growth by antiangiogenesis: involvement of vascular endothelial growth factor. *Nat Med.* 2002; 8:128–135. [PubMed: 11821896]
138. Perry B, Banyard J, McLaughlin ER, Watnick R, Sohn A, Brindley DN, et al. AKT1 overexpression in endothelial cells leads to the development of cutaneous vascular malformations in vivo. *Arch Dermatol.* 2007; 143:504–506. [PubMed: 17438183]
139. Phung TL, Ziv K, Dabydeen D, Eyiah-Mensah G, Riveros M, Perruzzi C, et al. Pathological angiogenesis is induced by sustained Akt signaling and inhibited by rapamycin. *Cancer Cell.* 2006; 10:159–170. [PubMed: 16904613]
140. Kwon YS, Hong HS, Kim JC, Shin JS, Son Y. Inhibitory effect of rapamycin on corneal neovascularization in vitro and in vivo. *Invest Ophthalmol Vis Sci.* 2005; 46:454–460. [PubMed: 15671269]
141. Loewe R, Oble DA, Valero T, Zukerberg L, Mihm MC Jr, Nelson JS. Stem cell marker up-regulation in normal cutaneous vessels following pulsed-dye laser exposure and its abrogation by concurrent rapamycin administration: implications for treatment of port-wine stain birthmarks. *J Cutan Pathol.* 2010; 37(Suppl):76–82. [PubMed: 20482679]
142. Svaasand LO, Aguilar G, Viator JA, Randeberg LL, Kimel S, Nelson JS. Increase of dermal blood volume fraction reduces the threshold for laser-induced purpura: implications for port wine stain laser treatment. *Lasers Surg Med.* 2004; 34:182–188. [PubMed: 15004832]
143. Aguilar G, Franco W, Liu J, Svaasand LO, Nelson JS. Effects of hypobaric pressure on human skin: implications for cryogen spray cooling (part II). *Lasers Surg Med.* 2005; 36:130–135. [PubMed: 15704166]
144. Aguilar G, Svaasand LO, Nelson JS. Effects of hypobaric pressure on human skin: feasibility study for port wine stain laser therapy (part I). *Lasers Surg Med.* 2005; 36:124–129. [PubMed: 15704161]
145. Tan OT, Whitaker D, Garden JM, Murphy G. Pulsed dye laser (577 nm) treatment of portwine stains: ultrastructural evidence of neovascularization and mast cell degranulation in healed lesions. *J Invest Dermatol.* 1988; 90:395–398. [PubMed: 2450146]
146. Bezemer R, Heger M, van den Wijngaard JP, Mordon SR, van Gemert MJ, Beek JF. Laser-induced (endo)vascular photothermal effects studied by combined brightfield and fluorescence microscopy in hamster dorsal skin fold venules. *Opt Express.* 2007; 15:8493–8506. [PubMed: 19547183]
147. Heger M, Salles II, Bezemer R, Cloos MA, Mordon SR, Bégu S, et al. Laser-induced primary and secondary hemostasis dynamics and mechanisms in relation to selective photothermolysis of port wine stains. *J Dermatol Sci.* 2011; 63:139–147. [PubMed: 21664109]
148. Tan OT, Morelli JG, Whitaker D, Boll J, Murphy G. Ultrastructural changes in red blood cells following pulsed irradiation in vitro. *J Invest Dermatol.* 1989; 92:100–104. [PubMed: 2909620]
149. Black JF, Barton JK. Chemical and structural changes in blood undergoing laser photocoagulation. *Photochem Photobiol.* 2004; 80:89–97. [PubMed: 15339203]

150. Heger M, Beek J, Stenback K, Faber D, van Gemert M, Ince C. Darkfield orthogonal polarized spectral imaging for studying endovascular laser-tissue interactions in vivo—a preliminary study. *Opt Express*. 2005; 13:702–715. [PubMed: 19494931]
151. Heger M, Bezemer R, Huertas-Pérez JF, Dekker H, Beek JF. Endovascular laser-tissue interactions redefined: shining light on novel windows of therapeutic opportunity beyond selective photothermolysis. *Photomed Laser Surg*. 2010; 28:569–572. [PubMed: 20704498]
152. Aguilar G, Choi B, Broekgaarden M, Yang O, Yang B, Ghasri P, et al. An overview of three promising mechanical, optical, and biochemical engineering approaches to improve selective photothermolysis of refractory port wine stains. *Ann Biomed Eng*. Published online october 21, 2011.
153. Huertas-Perez JF, Heger M, Dekker H, Krabbe H, Lankelma J, Ariese F. Simple, rapid, and sensitive liquid chromatography-fluorescence method for the quantification of tranexamic acid in blood. *J Chromatogr A*. 2007; 1157:142–150. [PubMed: 17532325]

**CAPSULE SUMMARY**

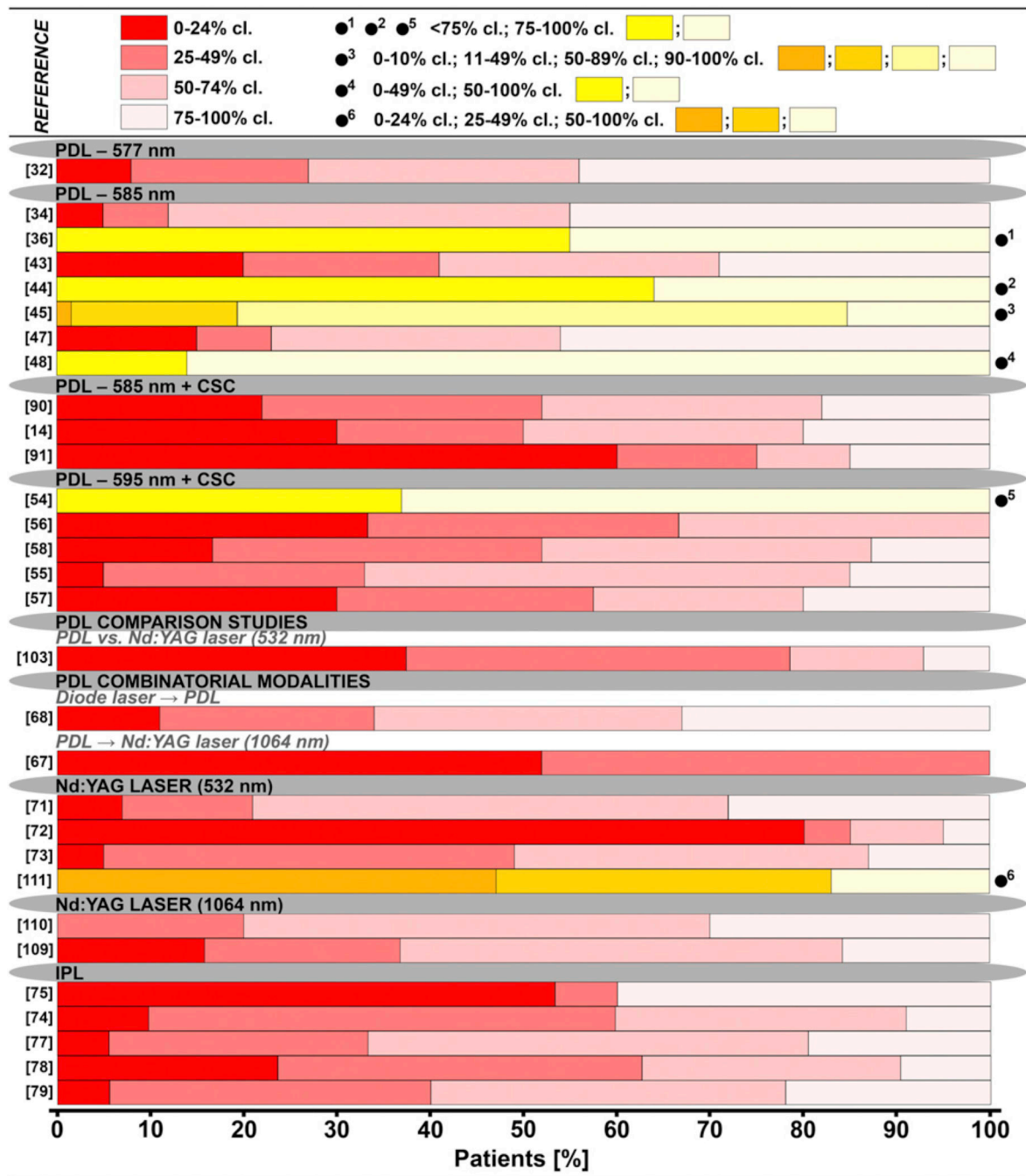
- The pulsed dye laser currently remains the treatment of choice for port wine stain (PWS) lesions. Despite innovations in various laser techniques and applications, the number of PWS refractory to current treatment modalities remains substantial.
- New experimental modalities are currently under investigation, including the use of photodynamic therapy, immune modulators, angiogenesis inhibitors, hemodynamic alterations in PWS vasculature, and site-specific pharmacolaser therapy.
- Alternative therapies will be required to increase the efficacy of PWS treatment.



**Fig 1.**

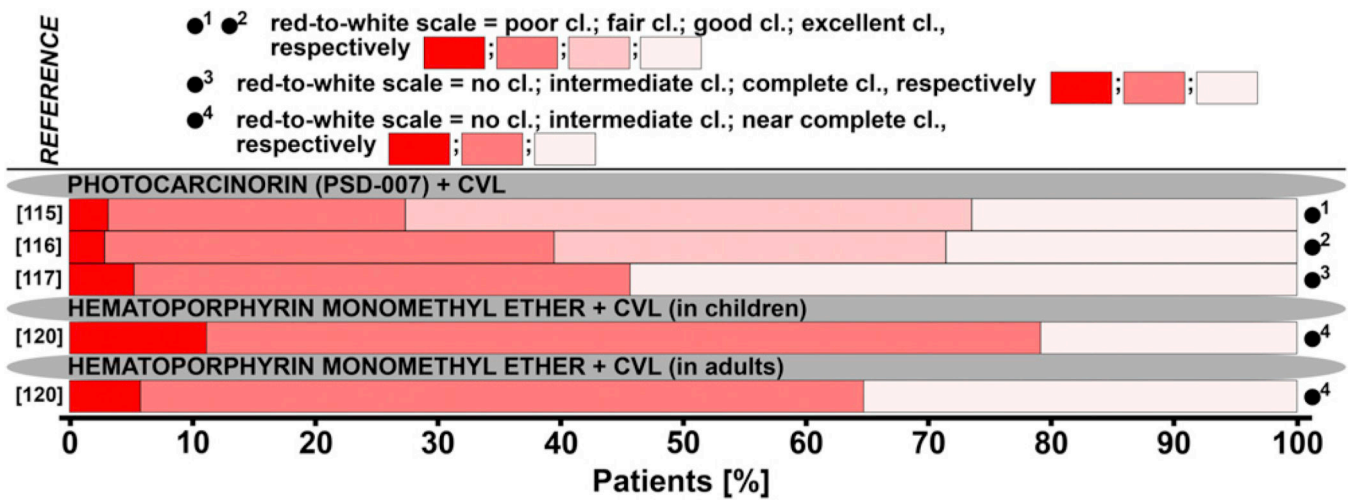
Overview of endovascular laser-tissue interactions in pulsed dye laser (PDL) treatment of refractory port wine stain (PWS) skin. Yellow light-emitting PDL is used to selectively photothermolyze ectatic venules (*blue structures*) in predominantly papillary dermis. Affected dermal segment is encircled, and acute and chronic responses are depicted in chronological order in panels from top to bottom. An approximate time frame in which events occur is indicated in upper left corner of each panel. Upon irradiation, photons are absorbed by hemoglobin-containing erythrocytes and converted to heat, resulting in thermal denaturation of blood and formation of thermal coagulum (photothermal response).<sup>9,11,12,146,148,149</sup> In refractory PWS vessels, one fraction of the vascular lumen is completely photocoagulated and another fraction is incompletely occluded by thermal coagula. Thermal coagula in latter trigger thrombosis (hemodynamic response).<sup>147</sup> It is believed that these processes induce an inflammatory reaction that culminates in vascular remodeling, whereby completely photo-coagulated vasculature is removed and replaced by

normal-sized capillaries through angio-genesis and/or neovasculogenesis. Because remodeled vasculature contains lower blood volume, PWS either lightens in redness or disappears entirely. In contrast, thermal coagula and thrombi in incompletely occluded structures are thought to be remodeled into restructured vascular lumen.<sup>24</sup> Image of skin and vascular anatomy courtesy of Libuše Markvart, used with permission.

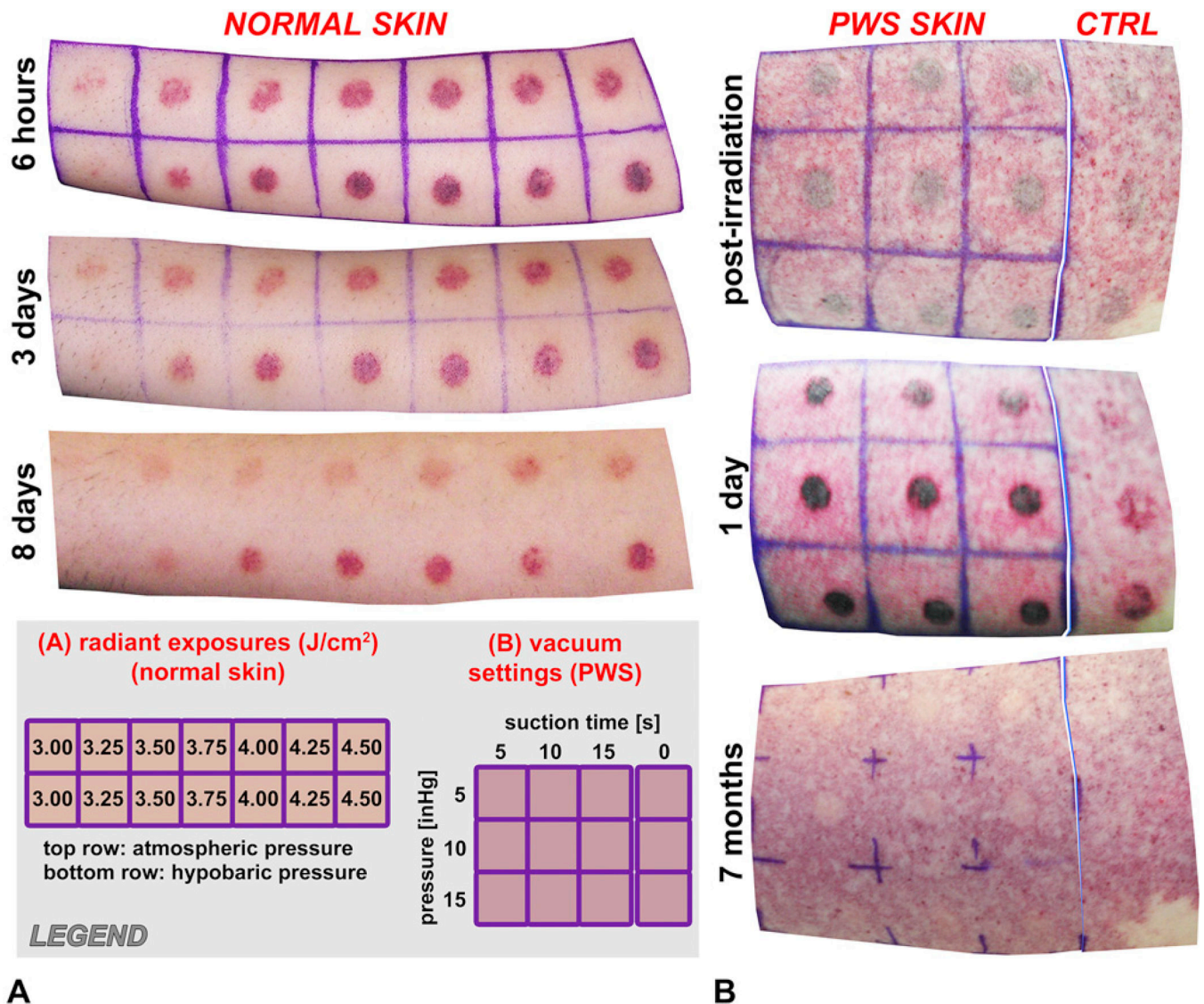


**Fig 2.** Overview of port wine stain treatment outcomes achieved by laser and intense pulsed light (IPL) systems from 1990 to present. Data are categorized by laser treatment modality, plotted as percentage of clearance (cl) (generally classified into 0%–24%, 25%–49%, 50%–74%, and 75%–100%), and color coded according to level of cl. Solid circle on right side of chart indicates different classification system as described in legend (top), which has been color coded in yellow/orange as indicated in legend. Each horizontal bar set represents entire patient population of study, referenced on left side of chart, whereby patient

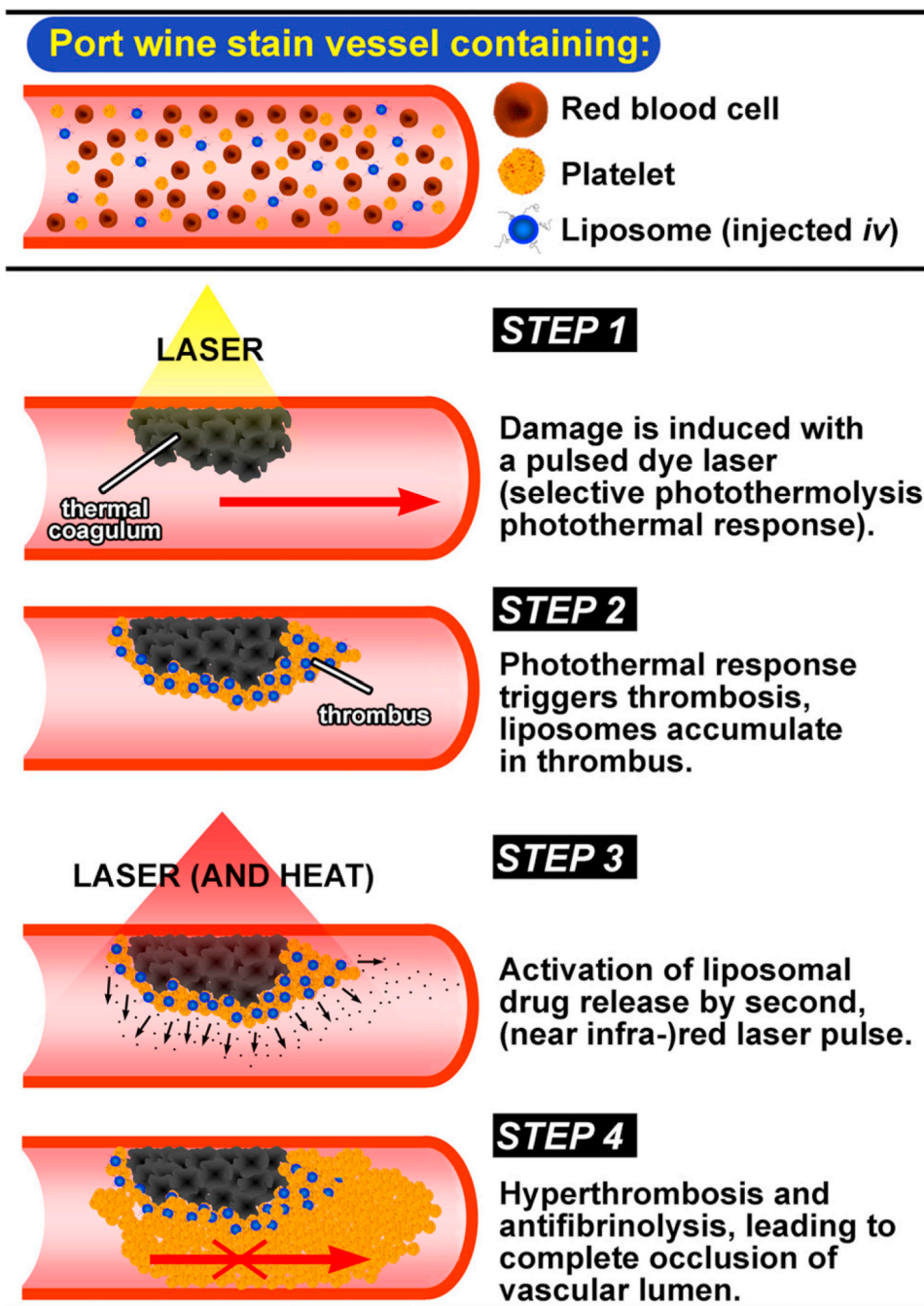
percentages are provided on bottom  $x$ -axis. Complete data set is presented in Table I. *CSC*, Cryogen spray cooling; *Nd:YAG*, neodymium:yttrium-aluminum-garnet; *PDL*, pulsed dye laser;  $\rightarrow$ , followed by IPL.



**Fig 3.** Overview of port wine stain treatment outcomes achieved with photodynamic therapy from 1990 to present. Data are plotted as percentage of clearance (*cl*) classified according to figure legend. *Solid circle* on right side of chart indicates type of classification system, which has been color coded according to level of *cl* as provided behind every legend entry. Each *horizontal bar set* represents entire patient population of study, referenced on left side of chart, whereby patient percentages are provided on bottom *x-axis*. Complete data set is presented in Table II. *CVL*, Copper vapor laser.



**Fig 4.** Pulsed dye laser-induced (585 nm) purpura on inner forearm in absence of and after application of pressure cuff in healthy volunteer (**A**) and on back upper aspect of arm in patients with port wine stain (*PWS*) at increasing vacuum pressures and suction times (**B**). **A**, Healthy volunteers with Fitzpatrick skin types II and III were subjected to laser irradiation at radiant exposure as indicated in legend, and extent of purpura was imaged at indicated times after laser irradiation. Purpura induced without use of suction device (*top row*) or obtained after suction device was applied at 10 inHg for 3 minutes before laser irradiation (*bottom row*). **B**, Laser-induced purpura directly after laser irradiation, 1 day, and 7 months after laser irradiation of *PWS* skin at 6-J/cm<sup>2</sup> radiant exposure. Rows show hypobaric pressures applied before laser irradiation and columns indicate duration of applied vacuum (see legend). Column right of grid shows induced purpura without vacuum at same radiant exposure. Note obvious clearing in upper two rows after single laser pulse. Data modified and used with permission.<sup>144</sup> *CTRL*, Control.



**Fig 5.** Schematic representation of principles of site-specific pharmaco-laser therapy (SSPLT) for treatment of port wine stains (PWS). After intravenous (*iv*) administration of liposomes containing prothrombotic and/or antifibrinolytic agents, PWS vasculature will contain liposomal drug carriers and cells that are instrumental in SSPLT: red blood cells (nucleation centers during selective photothermolysis, required for triggering hemodynamic response via thermal coagulum formation) and platelets (mediators of thrombosis, required for targeting of liposomes) (*top*). First step of envisaged modality comprises induction of

thermal coagulum by laser irradiation according to current clinical practice. Direction of blood flow ( $\rightarrow$ ). This leads to subsequent induction of thrombosis in semiphotocoagulated blood vessels,<sup>147</sup> whereby circulating liposomes are targeted to activated platelets in developing thrombus (step 2). Subsequently, irradiation of laser-treated PWS using near infrared light will locally generate heat that causes liposomes to release encapsulated pharmaceutical agents (step 3, *arrows* and *dots*)<sup>153</sup> in vicinity of laser-induced, semiobstructive thermal coagulum. Release of prothrombotic and antifibrinolytic agents promotes hyperthrombosis and deterrence of fibrinolysis, culminating in thrombotic occlusion and hemostasis of blood vessel that otherwise would have remained incompletely photo-occluded ( $\text{---X}\rightarrow$ ). Because this damage profile is comparable to completely photocoagulated vasculature,<sup>24</sup> SSPLT may prove promising in improving lesional clearance rates.